

Epidural Injection with Only Local Anesthetic for Lumbosacral Radicular Pain: A Case Report

Federica Giuliatti^{1,*}, Catello Pellegrino², Alessandra Parini¹, Cristina Scala¹

¹Department of Emergency, Hospital “Principe di Piemonte”, Senigallia (An), Italy

²Department of Emergency, Marche Polytechnic University, Ancona, Italy

Email address:

federica.giuliatti75@gmail.com (Federica Giuliatti), catello.pellegrino@gmail.com (Catello Pellegrino)

*Corresponding author

To cite this article:

Federica Giuliatti, Catello Pellegrino, Alessandra Parini, Cristina Scala. Epidural Injection with Only Local Anesthetic for Lumbosacral Radicular Pain: A Case Report. *American Journal of Life Sciences*. Vol. 11, No. 4, 2023, pp. 64-71. doi: 10.11648/j.ajls.20231104.13

Received: June 4, 2023; **Accepted:** July 18, 2023; **Published:** August 31, 2023

Abstract: Lumbosacral radicular pain is a condition where pain originating in the lower back radiates down through the hips, buttocks and legs. While lumbosacral radicular pain primarily affects an individual's physical wellbeing, it can also have important social and economic implications. Additionally, the prevalence of lumbosacral pain is increasing worldwide. The epidural injections are an alternative approach to treat lumbosacral radicular pain instead of surgical therapy. Epidural steroid injections are often combined with local anesthetic and injected to reduce pain associated with conditions that cause inflammation and pain in the spine. It's worth noting that while epidural steroid injections can provide significant pain relief for many people, they are associated with potential risks and side effects. Epidural steroid injections can occasionally lead to allergic reactions in some individuals. If it is not possible to administer steroids in the epidural space due to patient's allergy, then we can administer only local anesthetic. Case report: A 70 years old woman came to our clinic complaining with acute pain in her left lumbar back and left leg related to her L5-S1 radiculopathy. The patient reported skin rash and angioedema after a previous epidural with only triamcinolone. Method: After signing the consent form, in a aseptic technique, the patient receives only the local anesthetic (bupivacaine 5 mg and ropivacaine 4 mg diluted with physiological solution for a total volume of 6 ml) in the lumbar epidural space at L4-L5 via interlaminar approach. Clinical evaluation was performed before the procedure, immediately after the injection and at one, three and six months after injection using Numeric Rating Scale (NRS) and Oswestry Disability Index (ODI). Results: The patient reports an immediate pain reduction (NRS 10 before local anesthetic injection, NRS 4 immediately after the injection). Still after three months post injection, the patient reports a reduction of pain intensity (NRS 3) with 30 % ODI index. Conclusion: Epidural steroid injections have been widely used for over 50 years in the treatment of low-back pain with radiculopathy but many doctors do not believe in the efficacy of corticosteroids administered in the epidural space. Recent reviews have disclosed controversial results and have questioned the effectiveness of epidural steroid injections. Injecting only local anesthetic in the epidural space eliminates the side effects associated with corticosteroids; therefore, it is possible to repeat injection more frequently. Further studies are needed to evaluate the true role of local anesthetic in the epidural level.

Keywords: Steroid, Local Anesthetic, Epidural Injection

1. Introduction

Epidural block is an effective and popular treatment modality for acute lumbar radicular pain, even though the long-term efficacy of this approach remains controversial [1-5].

Epidural injections (at cervical, dorsal, lumbar or caudal

level) for a hernia are commonly performed by introducing into the epidural space local anesthetic, to relieve the pain immediately, and corticosteroids with the aim of reducing the local inflammatory process and, consequently, the pain associated with it.

Many studies declare that lumbar disc herniation can be spontaneously absorbed without surgical treatment.

However, the pathogenesis and physiological indications

for predicting protrusion reabsorption are still unclear, which prevents clinicians from preferentially choosing conservative treatment options for lumbar disc herniation patients with reabsorption effects [6].

Therapeutic epidural injection of drugs (local anesthetic \pm steroids) is the most popular non-surgical procedure to treat lumbosacral radicular pain.

There are three anatomical approaches commonly used for administering epidural corticosteroids: caudal, interlaminar and transforaminal approaches. The caudal approach is the earliest described technique and delivers the medication into the epidural space from the sacrococcygeal ligament through the sacral hiatus. With this approach larger volumes of medication are required in order to reach the target site but it is also considered the safest and easiest technique. With the interlaminar approach, the medication is delivered directly into the posterior space. However, the medication may have difficulty transiting from the posterior to ventral epidural space due to the presence of epidural ligaments or scar tissue. The transforaminal approach is the most recently proposed approach where the needle is inserted into the “safe Triangle” (i. e. pedicle at the superior border, lateral side of the vertebral body at lateral border, and the spinal nerve root at medial border) which delivers the medication at the target site of pathology (i. e. interspace between the spinal nerve and the herniated disk) [7].

Corticosteroids injected in the epidural space often cause important side effects such as a rise in blood sugar (potentially harmful in a diabetic patient), redness of the skin or throughout the body, a rise in blood pressure, headache, tinnitus, nausea and vomiting.

Furthermore, in a patient who had previously developed angioedema after lumbar epidural injection with triamcinolone, it was mandatory to avoid corticosteroids in the epidural space. We decided to inject only local anesthetics (short and long half-life) in the lumbar epidural space to relieve the pain preventing the patient from having a good quality of life. The results led to both good short and long-term pain control.

We hypothesized that epidural injection with only local anesthetic could effectively alleviate lower radicular pain associated with lumbar disc herniation. One potential mechanism of action of local anesthetic includes the washout of inflammatory cytokines or dissolution of scar tissue in the long term.

Further studies are needed to prove this hypothesis.

2. Background

2.1. Pathophysiology of Radiculopathy

Radiculopathy is caused by inflammation and mechanical compression of the nerve root. Inflammation plays a major role in the evolution of radiculopathy [8]. Clinically, a large herniation of an intervertebral disc associated with significant neural compression may be asymptomatic, whereas severe radicular pain may exist without detectable root compression.

Also, the size or shape of herniation, and eventual change in size or shape does not correlate with clinical presentation or course [9, 10]. This shows the importance of inflammation in the pathophysiology of radiculopathy. The damaged structures release various inflammatory mediators, which trigger inflammatory reaction in the spine. For instance, the damaged facet joints release bradykinin, serotonin, norepinephrine, and interleukin (IL)-1. Also, the nerve endings of the posterior longitudinal ligament, outer annulus, facet capsule, or periosteum release substance P, vasoactive intestinal peptide, and calcitonin gene-related peptide. The nucleus pulposus generates inflammatory mediators, including phospholipase A2 (PLA2), prostaglandin E2, IL-1 α , IL-1 β , IL-6, tumor necrosis factor, and nitric oxide, and it is well known that discogenic pain is mediated by these inflammatory mediators and neovascularization induced by chemical signaling [11, 12]. PLA2 is the rate-limiting factor involved in the synthesis of arachidonic acid, which is the principal substrate in the cyclo-oxygenase and lipo-oxygenase pathways. Prostaglandins, along with other arachidonic acid by products, can cause or exacerbate pain mediated via inflammatory mechanisms and sensitization of peripheral nociceptors [13, 14]. Among the inflamed structures, the dorsal root ganglion is more sensitive to mechanical pressure than the nerve root [12].

2.2. Local Anesthetics in the Epidural Space

Local anesthetics are the mainstay of therapy for obtaining analgesia or anesthesia with an epidural. Understanding the pharmacology of local anesthetics is therefore paramount [15]. The choice of local anesthetic is based on desired length of action. Regardless of the class of local anesthetic, these drugs can be divided into short, intermediate, or long acting agents. The shortest-acting local anesthetic agent is chloroprocaine. Its short length provides ample anesthesia for short surgical procedures, and its quick elimination obviates the need for prolonged recovery room discharges. Lidocaine has traditionally been the agent of choice for slightly longer surgical procedures that require an intermediate-acting local anesthetic. In place of lidocaine, some centers have also adopted the use of mepivacaine for its longer length of action with a similar onset profile. The intermediate length of action of either agent can be prolonged by the addition of epinephrine. Of note is the potential for an increased incidence of hypotension due to venous pooling from the beta effects of epinephrine containing solutions. This phenomenon seems to be mostly true of patients receiving lumbar epidural analgesia. Longer-acting local anesthetics used for epidural blockade typically consist of either bupivacaine or ropivacaine in different concentrations. Greater concentrations of either will produce a greater motor block in addition to the sensory block that is typically desired. Ropivacaine, an analog of mepivacaine, has a lesser intense and shorter duration of motor block in addition to a lower toxicity profile than an equivalent dose of bupivacaine [16]. The cardiac toxicity profile of bupivacaine is the highest among all the choices of local anesthetics. It is due to a high degree of protein binding

and a greater blocking effect on cardiac sodium channels [15].

Local anesthetics generally block the generation of the action potential in nerve cells by increasing the threshold for electrical excitation with the blockade of voltage-gate sodium channels [17]. However, a plethora of different ion channels, receptors, and other molecular targets have been shown to be additional targets of local anesthetics, as shown predominantly from experimental studies on lidocaine [18].

The local anesthetic administration in the epidural space has various functions; in particular, being responsible for the analgesia after the epidural injection, it gives us the assurance that the pharmacological mixture has wetted the root responsible for the pain; moreover, the local anesthetic could have an anti-inflammatory action by acting on the cyclo-oxygenase cascade.

Bupivacaine is an amide type local anesthetic with a prolonged duration of effect compared with lidocaine [19] and may induce ventricular arrhythmias and cardiotoxicity at lower doses than lidocaine [20].

Ropivacaine is a highly lipid soluble local anesthetic with the advantage of being less arrhythmogenic and toxic for the central nervous system and cardiovascular system than bupivacaine [21]. Ropivacaine was approved by Food and Drug Administration (FDA) for surgical anesthesia and acute pain management; for acute postoperative pain management or control of labor pain, ropivacaine is used for continuous infusion or intermittent bolus via epidural catheter.

Levobupivacaine is the S (-) isomer of bupivacaine and produced longer duration of motor block when compared with racemic bupivacaine in dogs. However, the dose-dependent analgesic and motor-blocking effects of epidurally administered levobupivacaine and racemic bupivacaine (0.25, 0.5, and 0.75%) were similar in conscious dogs [22]. Like ropivacaine, levobupivacaine is less arrhythmogenic and cardiotoxic than bupivacaine [23].

2.3. Corticosteroid

Epidural corticosteroid injections are used frequently for the treatment of radicular pain because they control inflammation and suppress the edema of nerve root. Epidural steroid injection is widely used to treat different back pain conditions caused by, for example, herniated intervertebral disc and spinal stenosis.

Corticosteroid injectable agents are divided into two groups: non-particulate and particulate. Non-particulate corticosteroids are faster in onset but have much shorter acting anti-inflammatory properties. On the other hand, particulate corticosteroids have a slower onset with a longer anti-inflammatory effect. Particulate corticosteroids include triamcinolone, methylprednisolone and betamethasone acetate and are insoluble in saline, local anesthetic and iodinated contrast agents, whereas non-particulate corticosteroids such as betamethasone sodium phosphate and dexamethasone are soluble in all agents. Methylprednisolone is the largest corticosteroid in size while betamethasone is the smallest one [24].

The mechanisms of action of steroids include suppression

of ectopic discharges from inflamed nerves as well as pro inflammatory cytokines, improvement of blood flow, and lysing of iatrogenic and inflammatory adhesions. In fact, radicular pain is caused not only by mechanical compression but also is due to inflammation of the affected nerve roots because nucleus pulposus of the intervertebral disc evokes an immune reaction mediated via inflammatory molecules.

Dexamethasone is a non-particulate steroid while triamcinolone and betamethasone are particulate steroids [29]. The use of steroids is linked to the risk of spinal cord injury [25].

The use of non-particulate steroids is recommended to minimize the complications associated with epidural steroids [11].

Reports of complications published in the past decade involving the use of epidural corticosteroids led the U. S. Food and Drug Administration in April 2014 to request that an additional warning be added for the epidural use of corticosteroids in the prescribing information of all available corticosteroids, including non particulate steroids [26, 27]. The appropriate interval and dosage of epidural steroid injection are disputed.

It was emphasized that epidural injection of steroids may cause spinal cord infarction, paraplegia, quadriplegia, cortical blindness, and stroke [28]. Furthermore, the epidural administration of corticosteroids has not officially been approved by the FDA or the European Medicines Agency (EMA), which means that it is classified as “ off-label” use [28].

Further, complications after epidural corticosteroid injection are: bone demineralization, suppression of the hypothalamic-pituitary-adrenal axis, adrenal insufficiency, immunology and infectious disease, elevated glucose level, flushing in the face, urticarial, nausea and vomiting, fever over the night after the intervention, sensitivity at the injection site, hypotension and insomnia [28].

3. Case Report

3.1. Material and Method

A 70 years old woman came to our clinic complaining about acute pain in her left lumbar and left leg related to her L5-S1 radiculopathy.

The patient had been suffering from this kind of pain for about one month; following the advice of her general practitioner, the patient had taken etoricoxib and tramadol without benefit. When she arrived at our clinic the patient was unable to walk and was crying in pain. As per her past medical history, the patient underwent a thyroidectomy for multinodular goiter and was suffering from high blood pressure and osteoporosis. Furthermore the patient reported skin rash and angioedema after a previous epidural with only triamcinolone. She reported that the angioedema resolved after nebulized adrenaline.

Her weight was 75 Kg and her height was 165 cm.

The computer tomography showed disc herniation at L4-L5

level. In particular, in the computer tomography report was written: “left poster-lateral disc herniation with compression on the dural sac and left foraminal involvement; finding of expelled disc fragment in the left caudal recess”.

After signing the consent form, in an aseptic technique, the patient receives only the local anesthetic (bupivacaine 5 mg and ropivacaine 4 mg diluted with physiological solution for a total volume of 6 ml) in the lumbar epidural space at L4-L5

via interlaminar approach.

Leg pain intensity was measured using a Numeric Pain Rating Scale (NPRS o NRS) and disability was measured by Oswestry Disability Index (ODI).

NRS and ODI score were detected before epidural injection, immediately after the injection and at one, three and six months after epidural injection.

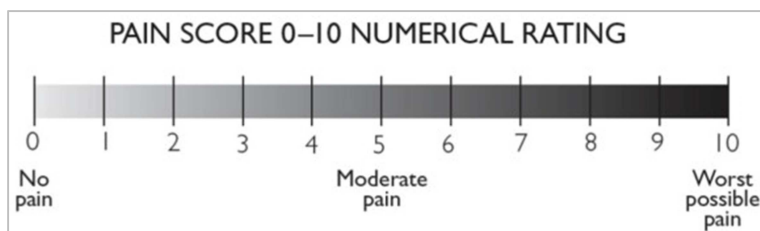


Figure 1. Numeric Rating Scale (NRS).

<p>Section 1- Pain Intensity</p> <ul style="list-style-type: none"> ▪ I have no pain at the moment ▪ The pain is very mild at the moment ▪ The pain is moderate at the moment ▪ The pain is fairly severe at the moment ▪ The pain is very severe at the moment ▪ The pain is the worst imaginable at the moment <p>Section 2- Personal care (washing, dressing, etc..)</p> <ul style="list-style-type: none"> ▪ I can look after myself normally without causing extra pain ▪ I can look after myself normally but it causes extra pain ▪ It is painful to look after myself and I am slow and careful ▪ I need some help but manage most of my personal care ▪ I need help every day in most aspects of self-care ▪ I do not get dressed, I wash with difficulty and stay in bed <p>Section 3- Lifting</p> <ul style="list-style-type: none"> ▪ I can lift heavy weights without extra pain ▪ I can lift heavy weights but it gives extra pain ▪ Pain prevents me from lifting heavy weights off the floor, but I can manage if they are conveniently placed e.g. on a table ▪ Pain prevents me from lifting heavy weights but I can manage light to medium weights if they are conveniently positioned ▪ I can lift very light weights ▪ I cannot lift or carry anything in all <p>Section 4- Walking</p> <ul style="list-style-type: none"> ▪ Pain does not prevent me walking any distance ▪ Pain prevents me from walking more than 2 Kilometers ▪ Pain prevents me from walking more than 1 Kilometers ▪ Pain prevents me from walking more than 500 meters ▪ I can only walk using a stick or crutches ▪ I am in bed most of the time <p>Section 5- Sitting</p> <ul style="list-style-type: none"> ▪ I can sit in any chair as long as I like ▪ I can only sit in my favorite chair as long as I like ▪ Pain prevents me sitting more than one hour ▪ Pain prevents me sitting more than 30 minutes ▪ Pain prevents me sitting more than 10 minutes ▪ Pain prevents from sitting at all 	<p>Section 6- Standing</p> <ul style="list-style-type: none"> ▪ I can stand as long as I want without extra pain ▪ I can stand as long as I want but it gives me extra pain ▪ Pain prevents me from standing for more than 1 hour ▪ Pain prevents me from standing for more than 30 minutes ▪ Pain prevents me from standing for more than 10 minutes ▪ Pain prevents me from standing at all <p>Section 7- Sleeping</p> <ul style="list-style-type: none"> ▪ My sleep is never disturbed by pain ▪ My sleep is occasionally disturbed by pain ▪ Because of pain I have less than 6 hours sleep ▪ Because of pain I have less than 4 hours sleep ▪ Because of pain I have less than 2 hours sleep ▪ Pain prevents me from sleeping at all <p>Section 8- Sex life (if applicable)</p> <ul style="list-style-type: none"> ▪ My sex life is normal and causes no extra pain ▪ My sex life is normal but causes some extra pain ▪ My sex life is nearly normal but is very painful ▪ My sex life is severely restricted by pain ▪ My sex life is nearly absent because of pain ▪ Pain prevents any sex life at all <p>Section 9- Social Life</p> <ul style="list-style-type: none"> ▪ My social life is normal and gives me no extra pain ▪ My social life is normal but increases the degree of pain ▪ Pain has no significant effect on my social life apart from limiting my more energetic interests e.g. sport ▪ Pain has restricted my social life and I do not go out as often ▪ Pain has restricted by social life to my home ▪ I have no social life because of pain <p>Section 10- Travelling</p> <ul style="list-style-type: none"> ▪ I can travel anywhere without pain ▪ I can travel anywhere but it gives me extra pain ▪ Pain is bad but I manage journeys over two hours ▪ Pain restricts me to journeys of less than one hour ▪ Pain restricts me to short necessary journeys under 30 minutes ▪ Pain prevents me from travelling except to receive treatment
--	---

Figure 2. Oswestry Disability Index (ODI) [31].

MODIFIED ODI SCORE (%)	LEVEL OF DISABILITY
0-20	Minimal disability
21-40	Moderate disability
41-60	Severe disability
61-80	Cripple, pain impinges on all aspects of patient's
81-100	Patients are bed bound or exaggerating their symptoms

Figure 3. The modified Oswestry Disability Index (ODI) [32].

The Numeric Rating Scale (NRS) (Figure 1) is one-dimensional eleven point scale that rates pain intensity in adults. The patient indicates the intensity of the pain verbally or by drawing a circle on the number that best describes it. The scale consists of a horizontal line with a range from 0 to 10 corresponding respectively to “no pain” and “worst pain imaginable” [29]. In the literature there are other versions at 6, 7, 20, 21 and 101 points [30]. The NRS scale is easy to administer takes less than a minute to complete and does not require any visual-motor coordination.

The Oswestry Disability Index (ODI) (Figure 2) currently represents the gold standard for the assessment of disability in chronic low back pain and is widely used in clinical research studies both for its excellent psychometric characteristics and for its easy of administration as it takes about five minutes.

Beside devastating chronic pain, patients also suffer from

more general dysfunctions, including physical, emotional, social, recreational, vocational, financial, and legal fields.

The modified Oswestry Disability Index (ODI) (Figure 3) is obtained by adding the scores of each of the ten sections of the questionnaire (from 0 to 5 for each section), dividing this score by the total possible score (50 if all 10 sections were completed, 45 if a section was not completed) and converting this fraction to a percentage.

3.2. Tables

The tables (table 1 and table 2) show the recorded data of NRS and ODI % before epidural injection, immediately after epidural injection, after one month injection, after three month injection and after six month injection.

Table 1. NRS (Numeric Rating Scale).

TIME	NRS
Before epidural injection	10
Immediately after epidural injection	4
After one month from the injection	4
After three month from the injection	3
After six month from the Injection	3

Table 2. ODI score %.

TIME	ODI %
Before epidural injection	82
Immediately after epidural injection	40
After one month from the injection	35
After three month from the injection	30
After six month from the injection	30

3.3. Results

The patient reports an immediate pain reduction (Figure 4), (NRS 10 before the injection, NRS 4 immediately after the

injection). Still after three months injection the patient reports a further reduction of pain intensity with 30 % ODI index (Figure 5).

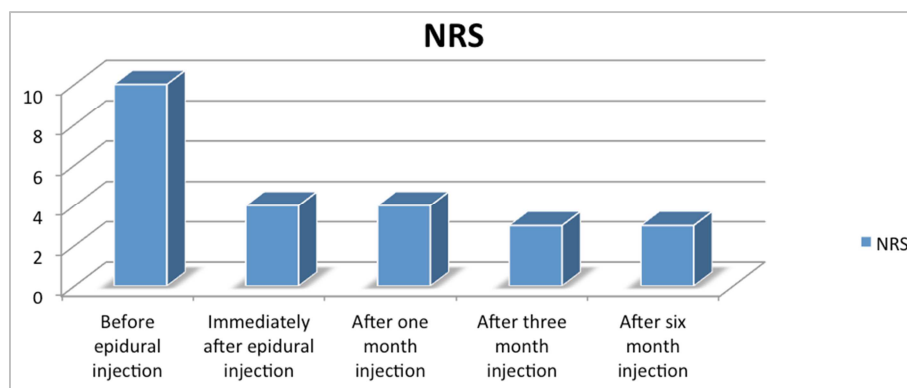


Figure 4. NRS.

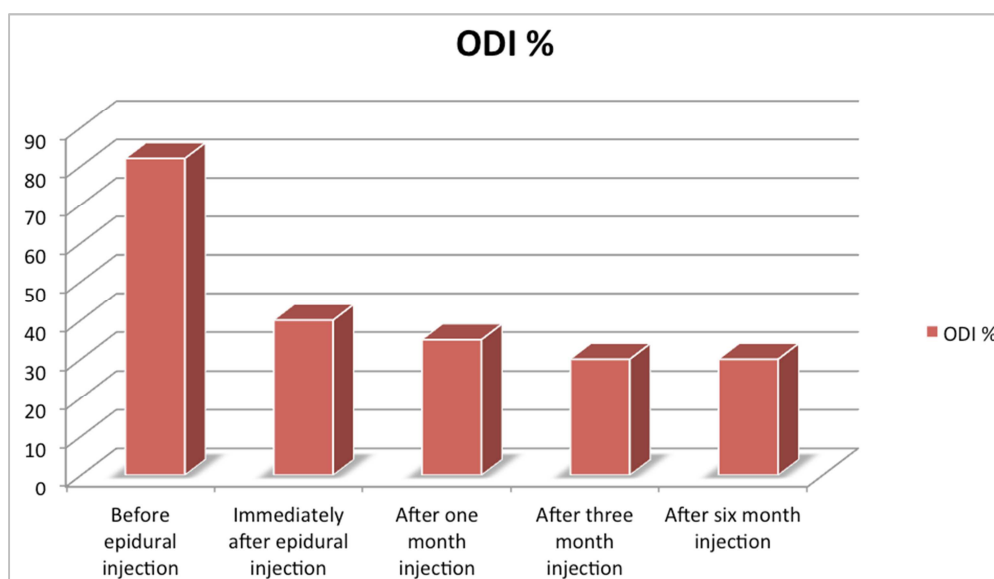


Figure 5. ODI %.

3.4. Discussion

In this clinical case we found that the use of local anesthetics alone (short and long half-life) reduced the intensity of pain immediately after the epidural injection.

The mechanism through which this pain reduction occurred is not clear: the local anesthetics themselves could have an anti-inflammatory action or they could have diluted the inflammatory cytokines which are responsible for the pain in the lumbar hernia.

A washout function of inflammatory cytokines has also been ascribed to local anesthetics [7].

Local anesthetics alone can have a comparable efficacy in terms of pain relief and there is no evidence that it could be enhanced by the addition of steroids. Some studies have reported similar degrees of pain relief and functional improvement in patients complaining neck pain secondary to disc herniation or affected by post-surgery syndrome who were treated with cervical epidural injections of local anesthetics \pm steroids [33, 34].

The difference in the use of a local anesthetic alone or local anesthetic with a corticosteroid in the epidural administration for the pain related to disk herniation has been investigated in numerous papers without a clear result [35, 36], although a meta-analysis study written by Lee *et al.* evidenced a small difference between the epidural injection of lidocaine vs lidocaine injection with corticosteroids [37].

It could have happened that the local anesthetic reduced the patient's pain and the hernia reabsorbed itself; or could have happened that the local anesthetic contributed directly to reabsorb of the hernia.

Further studies are needed to demonstrate this.

4. Conclusion

Epidural steroid injection have been widely used for over

50 years the treatment of low-back pain with radiculopathy. Most interventional pain physicians strongly believe in their efficacy and safety [38]. Recent Cochrane systematic review have disclosed controversial results and have questioned the effectiveness of epidural steroid injections. Moreover, epidural injection with only local anesthetics might spare selected patients of the side effects of steroids (nausea, headache, dizziness, vasovagal attack, flushing of the face [39]) and so repeat injection more frequently if necessary. The local anesthetic administration in the epidural space has multiple effects; specifically, being responsible for the analgesia after the epidural injection, it gives us the information that the pharmacological mixture has wetted the root responsible for the pain; moreover, the local anesthetic could have an anti-inflammatory action by acting on the cyclo-oxygenase cascade.

Further studies are needed to evaluate the true role of local anesthetics in the epidural space.

References

- [1] Bogduk N Epidural steroids. *Spine (Phila PA 1976)* 195; 20 (7): 845-848.
- [2] Cuckler JM, Bernini PA, Wiesel SW, Booth RE. Jr, Rothman RH, Pickens GT. The use of epidural steroids in the treatment of lumbar radicular pain. A prospective, randomized, double-blind study. *J Bone Joint Surg Am* 1985; 67 (1): 63-66.
- [3] Derby R, Kine G, Saal JA, Reynolds J, Goldthwalte N, White AH, *et al.* Response to steroid and duration of radicular pain as predictors outcome. *Spine (Phila Pa 1976)* 1992; 17 (6) Suppl: S176-S183.
- [4] Van Tulder MW, Koes BW, Bouter LM Conservative treatment of acute and chronic nonspecific low back pain. A systematic review of randomized controlled trials of the most common interventions. *Spine (Phila Pa 1976)* 1997; 22 (18): 2128-2156.

- [5] Ji Seon Chae, Won-joong Kim, Se Hee Choi Effects of Local Anesthetics With or Without Steroids in Hig-Volume. Transforaminal Epidural Blocks for Lumbar Disc Herniation: A Randomized Double-Blind, Controlled Trial. *Journal of Korean Medical Science* 2022 May 2; 37 (17): e 137.
- [6] Pengfei Yu, Feng Mao, Jingyun Chen, Xiaoying Ma, Yuxiang Dai, Guan hong Liu, Feng Dai and Jingtao Liu Characteristics and mechanisms of resorption in lumbar disc herniation *Arthritides Res Ther* 2022; 24: 205.
- [7] Crystian B Oliveira, Christopher G Maher, Manuela L Ferreira, Mark J Hancock, Vinicius Cunha Oliveira, Andrew J McLachlan, Bart W Koes, Paulo H Ferreira, Steven P Cohen, Rafael Zambelli Pinto (2020) Epidural corticosteroid injections for lumbosacral radicular pain *Cochrane Database Syst Rev*. 2020 Apr; 2020 (4): CD013577.
- [8] Mulleman D, Mammou S, Griffoul I, Watier H, Goupille P. Pathophysiology of disk-related sciatica. I.--Evidence supporting a chemical component. *Joint Bone Spine*. 2006; 73: 151-8.
- [9] Boden SD, Davis DO, Dina TS, Patronas NJ, Wiesel SW. Abnormal magnetic-resonance scans of the lumbar spine in asymptomatic subjects. A prospective investigation. *J Bone Joint Surg Am*. 1990; 72: 403-8.
- [10] Boos N, Rieder R, Schade V, Spratt KF, Semmer N, Aebi M. 1995 Volvo Award in clinical sciences. The diagnostic accuracy of magnetic resonance imaging, work perception, and psychosocial factors in identifying symptomatic disc herniations. *Spine (Phila Pa 1976)* 1995; 20: 2613-25.
- [11] Min Soo Lee and Ho Sik Moon Safety of epidural steroids: a review *Anesth Pain Med (Seoul)* 2021 Jan 31; 16 (1): 16-27.
- [12] McLain RF, Kapural L, Mekhail NA. Epidural steroid therapy for back and leg pain: mechanisms of action and efficacy. *Spine J*. 2005; 5: 191-201.
- [13] Kuslich SD, Ulstrom CL, Michael CJ. The tissue origin of low back pain and sciatica: a report of pain response to tissue stimulation during operations on the lumbar spine using local anesthesia. *Orthop Clin North Am*. 1991; 22: 181-7.
- [14] Olmarker K, Störkson R, Berge OG. Pathogenesis of sciatic pain: a study of spontaneous behavior in rats exposed to experimental disc herniation. *Spine (Phila Pa 1976)* 2002; 27: 1312-7.
- [15] Maria Bauer, John E. George III, John Self and Ehab Farag (2012) Recent Advances in Epidural Analgesia *Anesthesiol Res Pract*. 2012; 2012: 309219.
- [16] McClure JH. Ropivacaine. *British Journal of Anaesthesia*. 1996; 76 (2): 300-307.
- [17] Lirk P, Hollmann MW, Strichartz G. The science of local anesthesia: basic research, clinical application, and future directions. *Anesth Analg*. 2018; 126 (4): 1381-1392.
- [18] Hermanns H, Hollmann MW, Stevens MF, Lirk P, Brandenburger T, Piegeler T, et al. Molecular mechanisms of action of systemic lidocaine in acute and chronic pain: a narrative review. *Br J Anaesth*. 2019; 123 (3): 335-349.
- [19] Lawal FM, Adetunji A. A comparison of epidural anaesthesia with lignocaine, bupivacaine and a lignocaine-bupivacaine mixture in cats. *J S Afr Vet Assoc* (2009) 80: 243-6.
- [20] Nath S, Haggmark S, Johansson G, Reiz S. Differential depressant and electrophysiologic cardiotoxicity of local anesthetics: an experimental study with special reference to lidocaine and bupivacaine. *Anesth Analg* (1986) 65: 1263-70.
- [21] Arthur GR, Feldman HS, Covino BG. Comparative pharmacokinetics of bupivacaine and ropivacaine, a new amide local anesthetic. *Anesth Analg* (1998) 67: 1053-8.
- [22] Gomez de Segura IA, Menafo A, Garcia-Fernandez P, Murillo S, Parodi EM. Analgesic and motor-blocking action of epidurally administered levobupivacaine or bupivacaine in the conscious dog. *Vet Anaesth Analg* (2009) 36: 485-94.
- [23] Leone S, Di Cianni S, Casati A, Fanelli G. Pharmacology, toxicology, and clinical use of new long acting local anesthetics, ropivacaine and levobupivacaine. *Acta Biomed* (2008) 79: 92-105.
- [24] Derby R, Lee SH, Date ES, Lee JH, Lee CH. Size and aggregation of corticosteroids used for epidural injections. *Pain Med*. 2008; 9 (2): 227-234.
- [25] Tobias J. Dietrich, Reto Sutter, Johannes M. Froehlich, Christian W. A. Pfirrmann Particulate versus non-particulate steroids for lumbar transforaminal or interlaminar epidural steroid injections: an update *Skeletal Radiology volume 44, pages149-155 (2015)*.
- [26] U. S. Food and Drug Administration. Epidural steroid injections (ESI) and the risk of serious neurologic adverse reactions in: Anesthetic and Analgesic Drug Products Advisory Committee, ed Anesthetic and Analgesic Drug Products Advisory Committee: Briefing Document. *Silver Spring, MD: US Food and Drug Administration; 2014: 8-56*.
- [27] Racoosin JA, Seymour SM, Cascio L, Gill R. Serious neurologic events after epidural glucocorticoid injection—the FDA’s risk assessment . *N Engl Med*. 2015; 373: 2299-2301.
- [28] Koen Van Boxem, Mienke Rijdsdijk, Guy Hans, Jasper de Jong, Jan Willem Kallewaard, Kris Vissers, Maarten van Kleef, James P. Rathmell and Jan Van Zundert. Safe Use of Epidural Corticosteroid Injections: Recommendations of the WIP Benelux Work Group *Pain Pract* 2019 Jan; 19 (1) 61-92.
- [29] Breivik H, Borchgrevink PC, Allen SM, et al. *Assessment of pain*. *British Journal of Anaesthesia*. 2008; 101 (1): 17-24.
- [30] Hjermstad MJ, Fayers PM, Haugen DF, et al. Studies comparing numerical rating scales, verbal rating scales, and visual analogue scales for assessment of pain intensity in adults: a systematic literature review. *Journal of Pain and Symptom Management*. 2011; 41 (6): 1073-1093.
- [31] Michelle Costa, L. Marshman Sex life and the Oswestry Disability Index *The spinal journal* 2015, Volume 15, Issue 6, 1 June 2015, Pages 1225-1232.
- [32] Nizar Abdoul jalil, Zaharah Sulaiman, Mohamed Saufi Awang, Mohamarowl Omar Retrospective Review of Outcomes of a Multimodal Chronic Pain Service in a Major Teaching Hospital: A Preliminary Experience in Universiti Sains Malaysia brief communication - *Multimodal chronic pain service Malaysian Journal of Medical Sciences, Vol. 16, No. 4, Pg 55-65, October - December 2009*.
- [33] Manchikanti L., Malla Y., Cash K. A., Pampati V., Hirsch J. A. Comparison of effectiveness for fluoroscopic cervical interlaminar epidural injections with or without steroid in cervical post-surgery syndrome. *The Korean journal of pain* . 2018; 31 (4): 277-288.

- [34] Bang-zhi Li, ' Wen-hai Tang, Yang Li, Lei Zhou, Ming-guo Liu and Sheng-Xue Bao Clinical Efficacy of Epidural Injections of Local Anesthetic Alone or Combined with Steroid for Neck Pain: A Systematic Review and Meta-Analysis *Biomed Res Int.* 2022; 2022: 8952220.
- [35] Manchikanti L., Cash K. A., Pampati V., Falco F. J. E. Transforaminal epidural injections in chronic lumbar disc herniation: A randomized, double-blind, active-control trial. *Pain Physician.* 2014; 17: 489–501.
- [36] Manchikanti L., Singh V., Cash K. A., Pampati V., Falco F. J. E. A randomized, double-blind, active-control trial of the effectiveness of lumbar interlaminar epidural injections in disc herniation. *Pain Physician.* 2014; 17: 61–74.
- [37] Lee J. H., Shin K.-H., Park S. J., Lee G. ., Lee C.-H., Kim D. H., Kim D. H., Yang H. S. Comparison of Clinical Efficacy Between Transforaminal and Interlaminar Epidural Injections in Lumbosacral Disc Herniation: A Systematic Review and Meta-Analysis. *Pain Physician.* 2018; 21: 433–448.
- [38] Michel Benoist, Philippe Boulu and Gilles Hayem Epidural steroid injections in the management of low-back pain with radiculopathy: an update of their efficacy and safety (2012) *Eur Spine J.* 2012 Feb; 21 (2): 204–213.
- [39] Manchikanti L, Buenaventura RM, Manchikanti KN, et al. (2012) Effectiveness of therapeutic lumbar transforaminal epidural steroid injections in managing lumbar spinal pain". *Pain Physician.* 2012; 15 (3): E199-245.